



PRESENTING CLINICAL SIGNS

DATE History: Grade IV left-sided murmur. Asymptomatic.

ECHOCARDIOGRAPHIC FINDINGS

5/2/22 2D, M-mode, and Doppler study.

PERFORMED BY:

Dr. Meredith Swart

INTERPRETED BY

Keith Blass, DVM,
MS, DACVIM
(Cardiology)

There is moderate left atrial dilation. The mitral valve leaflets are thickened and exhibit mild systolic prolapse. There is Doppler evidence of mitral regurgitation present. There is moderate left ventricular dilation. Left ventricular systolic function is normal. The aorta and aortic valve are normal. Right atrial and right ventricular dimensions are normal. The tricuspid valve is normal. The pulmonary artery and pulmonic valve are normal. No pericardial effusion or cardiac masses are seen.

LA - 51.9 mm
LVIDd - 52.6 mm
LVIDs - 32.8 mm
FS - 37.6%

PATIENT

Buddy Richardson

RA - 29.2 mm
LVOT - 2.11 m/s
RVOT - 1.00 m/s

SPECIES

Canine

ASSESSMENT/RECOMMENDATIONS

Degenerative mitral valve disease

BREED

Pit Bull Mix

This examination demonstrates regurgitation of blood across Buddy's mitral valve resulting from degenerative valve disease. Secondary to his regurgitation, Buddy has moderate dilation of both his left atrium and left ventricle, though his left ventricular systolic function is normal. While Buddy is currently asymptomatic, the severity of his disease indicates that he is at risk for the development of clinical signs, such as coughing, exercise intolerance, syncope, and labored breathing, therefore, careful monitoring for these signs is recommended.

SEX

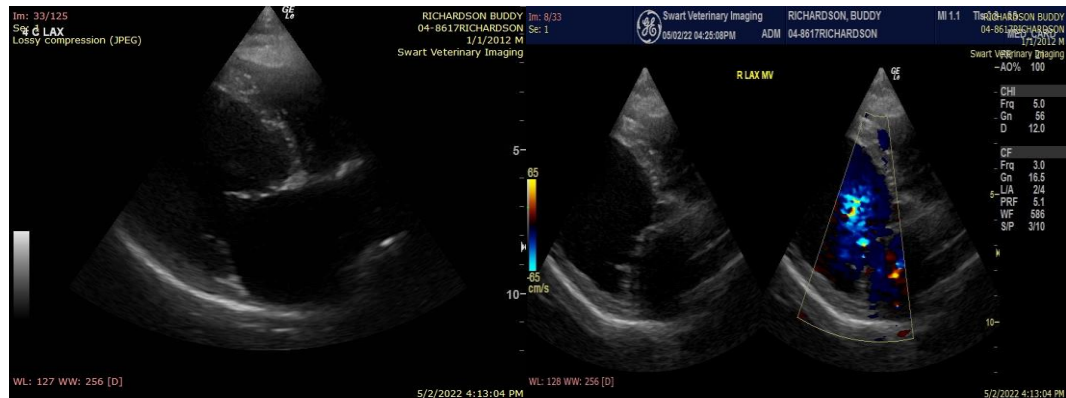
I recommend starting Buddy on pimobendane (5 mg BID), as this medication should help to slow the progression of his mitral valve disease.

MN

A recheck echocardiogram is recommended in ~9 months. Thoracic radiographs are recommended if Buddy experiences respiratory clinical signs.

AGE

10 y



WEIGHT

44 lb

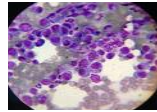
HOSPITAL NAME

Swart Veterinary
Imaging

REFERRING VET

Dr. Swart

The information and recommendations provided are based on the images presented by the referring veterinarian. No evaluation can be communicated regarding pathology that was not visible in the image/video clips provided.



DATE

Thank you for this referral. If the clinical or image interpretation does not parallel your findings or if I can be of any further assistance please contact me.

5/2/22

PERFORMED BY:

Keith Blass, DVM, MS, DACVIM (Cardiology)
KeithBlass@gmail.com
631-804-5754

Dr. Meredith Swart

INTERPRETED BY

Keith Blass, DVM,
MS, DACVIM
(Cardiology)

PATIENT

Buddy Richardson

SPECIES

Canine

BREED

Pit Bull Mix

SEX

MN

AGE

10 y

WEIGHT

44 lb

HOSPITAL NAME

Swart Veterinary
Imaging

REFERRING VET

Dr. Swart